



Review Article

Infantile Hepatic Hemangiomas: A Shrouded Mystery

Dr Pramod Singh Khatri¹, Sonam Pandey²¹Head of Department, Dept. of Clinical Research, Amity Medical School, Amity University, Gurgaon.²MSc Clinical Research, Amity Medical School, Amity University, Gurgaon

ARTICLE INFO

Article History:Received on 15th September, 2016Peer Reviewed on 08th October 2016Revised on 17th November, 2016Published on 02nd December, 2016Keywords:

Hepatic Hemangiomas, Infant Screening, Vascular tumors, liver hemangioma

ABSTRACT

Infantile hemangiomas (IHs) are the most widely recognized benign tumor of childhood, influencing up to 10% of the pediatric populace with a higher frequency in female (3:1), preterm newborn, and Caucasian populace. Most IHs are not present during childbirth but become ostensible a few days to a few weeks after birth. IHs are described by a fast-proliferative stage in the initial 6-10 months, trailed by a moderate involution, which can last up to 10 years. Despite their benevolent nature, IHs can result in serious morbidities and hence sometimes require therapeutic intervention. IHs can go from asymptomatic to life threatening. Vital functions, for example, breathing, vision, and bolstering can be impeded, contingent upon the area of the lesion. IHs are affirmed by positive immunostaining for glucose transporter-1 (GLUT-1), which is pathognomonic for the conclusion of IHs, and hence distinguishing IHs from other vascular anomalies. While most IHs are available in the skin, IHs can occur in the viscera, with or without cutaneous indications. The liver is the most widely recognized site of visceral IHs, trailed by the gastrointestinal system.

Screening for liver IHs (IHH) by ultrasonography (USG) is prescribed when 5 or more cutaneous IHs are distinguished. although, majority of IHHs are found as coincidental discoveries amid routine imaging. IHHs are distinguished in three diverse subtypes, focal, multifocal and diffuse IHH, based on the lingering unaffected liver parenchyma. Focal lesions will frequently involute quickly after birth with no complications. Multifocal lesions tend to involute in a cutaneous IHs, over a 6-10-year time span. Diffuse lesions have a tendency to supplant virtually whole liver parenchyma, with serious complications. These can incorporate cardiovascular failure, high volume arteriovenous shunting, hypothyroidism, bleeding. Therefore, once scrutinized, subjects with IHHs usually require close monitoring until complete involution of the lesions.

INTRODUCTION:

Infantile hemangioma (IH) is the most widely recognized pediatric tumor, influencing 4% to 5% of infant¹⁻³. It is a benign endothelial cell neoplasm that shows quick postnatal growth shadowed by moderate involution amid childhood. Nevertheless, roughly 10% to 20% of IHS cause vision-debilitating, life-threatening, or deforming complications⁴. The life cycle progresses in 3 phases: (1) a multiplying period of rapid development, starting after birth and enduring roughly 9 to 12 months;(2) an involuting stage, enduring 5 to 7 years, amid which apoptosis prevails over mitosis and free stromal tissue replaces the quickly dividing endothelial cells, myeloid cells, and pericytes that describe the underlying stage; and (3) an involuted stage portrayed by the enduring replacement of the lesion with fibrofatty tissue⁵⁻⁸. Albeit most IHS are cutaneous, visceral involvement additionally happens, regularly in the setting of different lesions (hemangiomatosis). Infantile hepatic hemangiomas (IHHs) offer the same patterns of development and regression. It is likely that most hepatic hemangiomas are clinically silent and stay undetected⁹. A few hemangiomas are found on routine pre-birth imaging or postnatal imaging. Another subset become symptomatic, showing as cardiovascular failure secondary to high volume shunting, hypothyroidism, fulminant hepatic failure¹⁰. Female infant are three times as liable to have hemangiomas when contrasted with male babies, and there is an expanded rate of premature and low-birth weight babies. Approximately 55% of these tumors are available during childbirth, and 45% develop within first weeks of life. Infants who are exposed to CVS at 9-12 weeks of gestation hemangiomas in 21% of cases¹¹.

The field of vascular abnormalities has risen in recent years as clinical, pathologic, and radiologic evidence has encouraged illumination of terminology. The conduct of true IHHs must be recognized from ordinarily incorrectly named hemangiomas of adulthood that are venous contortions and from Epithelioid hemangioendothelioma, a threatening tumor with metastatic potential¹². Sadly, IHH has additionally been called hemangioendothelioma, especially in the histopathologic literature. Infantile hepatic hemangioma has additionally been mistaken for hepatic arteriovenous distortions on the grounds that both show quick stream, shunting, and cardiac consequences¹³. This disarray has made the treatment

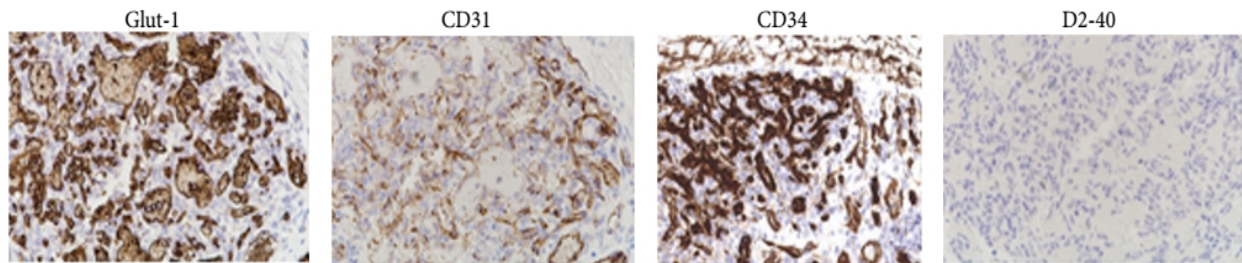
of IHHs random with apparently little rationale for picking between pharmacologic medicines (corticosteroid, interferon alfa-2a, or vincristine), embolization, surgical resection, hepatic artery ligation, and even hepatic transplantation¹⁴.

Prior to the modern classification system developed by Mulliken in 1982, and the latest subtyping of liver IHS by Christison-Lagay et al in 2007, there was extensive disarray. Phrasing for IHHs has been differed, a reality which can engender the perplexity and deferral in the right diagnosis and appropriate treatment of the influenced subjects¹⁵⁻¹⁷. In addition, there are a few other hepatic injuries that may impersonate diverse types of IHHs. Single hepatic lesions in a newborn child can likewise incorporate, hepatoblastoma, mesenchymal hamartoma, congenital cysts or Kaposi form hemangioendotheliomas (KHEs). IHHs have additionally been actually called "hemangioma endothelioma", regardless of the lesion type. Hence It is imperative to distinguish 3 subtypes of true IHHs from other benign and malignant liver lesions, as this can profoundly affect the management of these conditions¹⁸⁻¹⁹.

Genetic Mutations

Pathogenesis of Infantile hemangioma is still covered in puzzle, despite the fact that different hypotheses have been proposed to clarify its origin. Immunohistochemical investigations of hemangiomas affirm their vascular origin. Endothelial cells express cluster off differentiation- 31 (CD31), von Willebrand factor, vascular endothelial growth factor (VEGF), proliferating nuclear antigen and urokinase. An imbalance has been shown between the expression of angiogenic and antiangiogenic elements²⁰. Tissue inhibitors of metalloproteinase, a reported inhibitor of angiogenesis, are expressed in the involution stage. Endogenous steroid hormones (17-oestradiol) may assume a role in the growth of Infantile hemangiomas. Glucose transporter 1 (GLUT1), a glucose transporter typically expressed in the microvascular endothelia of blood-tissue barriers, for example, placenta, was recently portrayed as a particular marker for hemangioma vessels as it is missing in other vascular lesions, for example, mutation, RICH (rapid involuting congenital hemangioma) and NICH (non-involuting congenital hemangioma). SKI oncogene protein is differentially expressed in hemangioma tissues, prompting uncontrolled cell expansion and transformation²¹⁻²².

Figure 4: Positive endothelial cells for Glut-1, CD31 and CD34 however negative for D2-40 stain which identifies lymphangioma.



Clinical presentation

Haemangiomas are mostly small, asymptomatic and are identified incidentally when the liver is imaged for unrelated conditions or when the liver is inspected at laparotomy or post-mortem examination. Upper stomach pain or discomfort is the most well-known symptom, when the lesion gets to be symptomatic²³. Less normal complaints were nausea, anorexia, dyspepsia and early satiety, which are seen when huge haemangiomas. The torment is typically mellow however can get to be extreme because of thrombosis and aggravation of Glisson's capsule. Torment from an acute thrombosis can last up to three weeks and be linked with pyrexia and unhinging of liver functions. Examination is by and large ordinary and the main findings of significance, seen occasionally, are an enlarged liver or the presence of an arterial vessel bruit over the right upper quadrant²⁴.

The atypical demonstrations of hepatic hemangiomas comprise:

- High output cardiac failure from huge arteriovenous shunting, especially in the kids
- jaundice from compression of the bile ducts
- hypothyroidism refractory to hormone replacement therapy
- Gastrointestinal bleeding from haemobilia
- Pyrexia of obscure origin
- polymyalgia rheumatica, impervious to steroids
- Kasabach-Merritt disorder (KMS) is an uncommon and serious coagulation disorder described by significant thrombocytopenia, microangiopathic hemolytic anemia

In youngsters, cutaneous haemangiomas may serve as markers for hepatic haemangiomas. Huges JA et al found that asymptomatic hepatic haemangiomas ensued in almost 25% of infant having six or more or a single large cutaneous haemangiomas.

Diagnosis

In many cases, a hemangioma can be analyzed taking into account the history and physical examination. Although, unraveling between a deep hemangioma

and a vascular deformity might be grim²⁵. Hepatic haemangiomas have certain attributes that point towards the conclusion on ultrasonography, CT, MRI. A minority of lesions are nevertheless atypical and may require various imaging tests or routine arteriography or even surgical intercession to accomplish a certain finding. Plain stomach radiographs might be typical or may indicate confirmation of calcification inside the lesion. Although this calcification needs specificity in haemangiomas²⁶.

Ultrasound commonly uncovers a well divided, hyperechoic, homogeneous, mass. Color Doppler Sonography (CDS) can delineate intratumoural stream and peritumoural hepato-fugal portal stream in subjects with hepatic haemangiomas amalgamated by arteriportal shunt²⁷. The frequencies of intratumoural stream and peritumoural hepatofugal portal stream were as high as 88% and 80% for shallow (≤ 30 mm) lesions, and they were 40% and 35% for profound (>30 mm) lesions ($p=0.0012$; $p=0.0051$).

A non-contrast-enhanced CT scan of a haemangiomas normally shows a well demarcated hypo-thick mass. Calcifications might be seen in around 10 % of lesions. The lesions may inhibit as hyper dense relative to the encompassing parenchyma in subjects with fatty liver²⁸. The management of complexity medium results in fringe nodular or globular upgrade in the early stage (up to 95 percent of hemangiomas >4 cm in size), trailed by a centripetal shape or "filling in" amid the late stage. After a postponement of three or more minutes, the lesions traditionally opacify and remain isodense or hyperdense on deferred scans. Upgrade may however be missing in hemangiomas with large cystic regions or scar tissue.

MRI has risen recently as a profoundly precise, non-intrusive strategy for diagnosing haemangiomas in light of its high complexity resolution, absence of ionizing radiation, and the likelihood of performing functional imaging successions²⁹. This methodology has a sensitivity and specificity of >95 percent.

Commonly, the lesions have low intensity on T1-weighted pictures and are hyper intense on T2-weighted pictures. At the point when gadolinium diethylenetriaminepentaacetic corrosive (Gd-DTPA) is utilized as a contrast agent, the lesion upgrade in a manner like that seen on CT showing early fringe irregular nodular or globular enhancement on blood vessel scans with dynamic centripetal upgrade or "filling in" on deferred scans³⁰. Regularly, haemangiomas follow the signal intensity of blood and the presence of intra lesioned fibrosis brings about regions of low intensity on T2-weighted images. On High-b-value dispersion weighted, DW-MR Images, the lesions frequently indicate findings that recommend limited diffusion.

Treatment Modalities:

Systemic corticosteroids are the principal line treatment for infantile hemangiomas, particularly the substantial hemangiomas, which cause function disability or distortion³¹. Steroids cause upgraded expression of gene coding for mitochondrial cytochrome band glycoproteins like clusterin/ApoJ (markers of apoptosis), expanded vasoconstriction and hindrance of angiogenesis. Thus, steroids are shown in the treatment of Infantile hemangioma. The prescribed starting dosage is 2-3 mg/kg of prednisolone given every day as a solitary morning dosage, with better retort rate in the proliferative stage³²⁻³⁴.

Radiation treatment is seldom utilized given its carcinogenic risk and accessibility of better treatment choices, however might be considered if all else fails for infant with recalcitrant life-threatening hemangiomas. Sclerotherapy with 1 to 3 infusions of polidocanol has been utilized to get persuading results and is a reasonable and promising treatment. Local delivery of bisphosphonates as a potential treatment of hemangiomas is under clinical trials³⁴.

Closing Remarks:

Infantile hepatic hemangiomas signify a clinically diverse range of benign hepatic tumors. Life-threatening and confounded instances of hemangiomatosis are thought-provoking conditions particularly in the neonates. Other treatment includes corticosteroid, cyclophosphamide, and laser therapy. A novel methodical scheme enveloping clinical presentation, radiographic appearance, pathologic features, physiologic conduct, and normal (untreated) and treated history is presented alongside a proposed remedial calculation. For symptomatic, vague or muddled lesions, surgical management is the pillar of treatment however other more up to date, less intrusive modalities have emerged in recent decades. Treatment of IHHs has advanced quickly in the previous decade, particularly in the clinical studies of propranolol instead of the efficacy and high toxicity with long term corticosteroid treatment. The comprehension of IHHs

is likely nearing the tipping point into another revolution of clinical information and treatment.

References:

- (1) Mo JQ, Dimashkieh HH, Bove KE. GLUT1 endothelial reactivity distinguishes hepatic infantile hemangioma from congenital hepatic vascular malformation with associated capillary proliferation. *Hum Pathol* 2004;35(2):200-9.
- (2) Hernandez F, Navarro M, Encinas JL, et al. The role of GLUT1 immunostaining in the diagnosis and classification of liver vascular tumors in children. *J Pediatr Surg* 2005;40(5):801-4.
- (3) Lyons LL, North PE, Mac-Moune Lai F, et al. Kaposi form hemangioendothelioma: a study of 33 cases emphasizing its pathologic, immunophenotypic, and biologic uniqueness from Infantile hemangioma. *Am J Surg Pathol* 2004;28(5):559-68.
- (4) Hughes JA, Hill V, Patel K, et al. Cutaneous haemangioma: prevalence and sonographic characteristics of associated hepatic haemangioma. *Clin Radiol* 2004;59(3):273-80.
- (5) Metry DW, Hawrot A, Altman C, et al. Association of solitary, segmental hemangiomas of the skin with visceral hemangiomatosis. *Arch Dermatol* 2004;140(5):591-6.
- (6) Mulliken JB, Enjolras O. Congenital hemangiomas and infantile hemangioma: missing links. *J Am Acad Dermatol* 2004;50(6):875-82.
- (7) Berenguer B, Mulliken JB, Enjolras O, et al. Rapidly involuting congenital hemangioma: clinical and histopathologic features. *Pediatr Dev Pathol* 2003;6(6):495-510.
- (8) Mejides AA, Adra AM, O'Sullivan MJ, et al. Prenatal diagnosis and therapy for a fetal hepatic vascular malformation. *Obstet Gynecol* 1995;85(5 Pt 2):850-3.
- (9) Baer HU, Dennison AR, Mouton W, Stain SC, Zimmermann A, Blumgart LH. Enucleation of giant hemangiomas of the liver. Technical and pathologic aspects of a neglected procedure. *Ann Surg.* 1992;216(6):673
- (10) Bahirwani R, Reddy KR. Review article: the evaluation of solitary liver masses. *Aliment Pharmacol Ther.* 2008; 28(8):953-65.
- (11) Goodman Z. Benign tumors of the liver. In: Okuda K, Ishak KG. *Neoplasms of the liver*. Tokyo: Springer-Verlag; 1987:105-125.
- (12) Pudil J, Martinek J, Belsan T, Ryska M. Atypically localised hepatic haemangioma as a cause of dyspeptic syndrome. *Rozhl Chir.* 2006; 85(7):354-6.
- (13) Pateron D, Babany G, Belghiti J, Hadengue A, Menu Y, Flejou JF, Erlinger S, Benhamou JP. Giant hemangioma of the liver with pain, fever, and

- abnormal liver tests. Report of two cases. *Dig Dis Sci*. 1991; 36(4):524.
- (14) Kucherov IuI, Zhirkova IuV, Getman AN, Ivleva SA, Rekhviashvili MG. Clinical case of treatment of hepatic haemangioma by propranolol in the newborn. *Vestn Ross Akad Med Nauk*. 2014 ; (5-6):81-5.
 - (15) Bruce S, Downe L, Devonald K, Ellwood D. Noninvasive investigation of infantile hepatic hemangioma: a case study. *Pediatrics*. 1995; 95(4):595.
 - (16) Ito K, Taira K, Arai S. Intrahepatic bile duct dilatation with a liver cyst and hemangioma: report of a case. *Surg Today*. 2009; 39(3):256-60.
 - (17) Mikami T, Hirata K, Oikawa I, Kimura M, Kimura H. Hemobilia caused by a giant benign hemangioma of the liver: report of a case. *Surg Today*. 1998; 28(9):948-52.
 - (18) Birth M, Ortlepp J, Bontikous S, Amthor M, Weiser HF, Bruch HP. Intermittent activity-induced hemobilia caused by liver hemangioma. *Dig Surg*. 2000;17(3):292-6. Lee
 - (19) CW, Chung YH, Lee GC, Kim JY, Lee JS. A case of giant hemangioma of the liver presenting with fever of unknown origin. *J Korean Med Sci*. 1994; 9(2):200-4.
 - (20) Goswamy J, Rothera MP, Bruce IA. Failure of propranolol in the treatment of childhood haemangiomas of the head and neck. *J Laryngol Otol* 2011;125:1164-72.
 - (21) Leboulanger N, Fayoux P, Teissier N, Cox A, Van Den Abbeele T, Carrabin L, et al. Propranolol in the therapeutic strategy of infantile laryngotracheal hemangioma: A preliminary retrospective study of French experience. *Int J Pediatr Otorhinolaryngol* 2010;74:1254-7.
 - (22) McCuaig CC, Cohen L, Powell J, Hatami A, Marcoux D, Maari C, et al. Therapy of ulcerated hemangiomas. *J Cutan Med Surg* 2013;17:233-42.
 - (23) Saint-Jean M, Léauté-Labrèze C, Mazereeuw-Hautier J, Bodak N, Hamel-Teillac D, Kupfer-Bessaguet I, et al. Propranolol for treatment of ulcerated infantile hemangiomas. *J Am Acad Dermatol* 2011;64:827-32.
 - (24) Hermans DJ, van Beynum IM, Schultze Kool LJ, van de Kerkhof PC, Wijnen MH, van der Vleuten CJ. Propranolol, a very promising treatment for ulceration in infantile hemangiomas: A study of 20 cases with matched historical controls. *J Am Acad Dermatol* 2011;64:833-8.
 - (25) Metry D, Frieden IJ, Hess C, Siegel D, Maheshwari M, Baselga E, et al. Propranolol use in PHACE syndrome with cervical and intracranial arterial anomalies: Collective experience in 32 infants. *Pediatr Dermatol* 2013;30:71-89.
 - (26) Hernandez-Martin S, Lopez-Gutierrez JC, Lopez-Fernandez S, Ramirez M, Miguel M, Coya J, et al. Brain perfusion SPECT in subjects with PHACES syndrome under propranolol treatment. *Eur J Pediatr Surg* 2012;22:54-9.
 - (27) Snir M, Reich U, Siegel R, Zvulunov A, Friling R, Goldenberg-Cohen N, et al. Refractive and structural changes in infantile periocular capillary haemangioma treated with propranolol. *Eye (Lond)* 2011;25:1627-34.
 - (28) Wester ST, Johnson TE. Echographic evidence of regression of a periocular infantile capillary hemangioma treated with systemic propranolol. *Ophthalmic Surg Lasers Imaging* 2011;42 Online: e18-21.
 - (29) Cavalli R, Novotna V, Buffon RB, Gelmetti C. Multiple cutaneous and hepatic infantile hemangiomas having a successful response to propranolol as monotherapy at neonatal period. *G Ital Dermatol Venereol* 2013;148:525-30.
 - (30) Frieden IJ, Drolet BA. Propranolol for infantile hemangiomas: Promise, peril, pathogenesis. *Pediatr Dermatol* 2009;26:642-4.
 - (31) Chen XD, Ma G, Huang JL, Chen H, Jin YB, Ye XX, et al. Serum-level changes of vascular endothelial growth factor in children with infantile hemangioma after oral propranolol therapy. *Pediatr Dermatol* 2013;30:549-53.
 - (32) Malik MA, Menon P, Rao KL, Samujh R. Effect of propranolol vs prednisolone vs propranolol with prednisolone in the management of infantile hemangioma: A randomized controlled study. *J Pediatr Surg* 2013;48:2453-9.
 - (33) Bertrand J, McCuaig C, Dubois J, Hatami A, Ondrejchak S, Powell J. Propranolol versus prednisone in the treatment of infantile hemangiomas: A retrospective comparative study. *Pediatr Dermatol* 2011;28:649-54.
 - (34) Raphael MF, Breugem CC, Knol MJ, Bruijnzeel-Koomen CA, Kon M, et al. Treatment of infantile haemangiomas with atenolol: Comparison with a historical propranolol group. *J Plast Reconstr Aesthet Surg* 2013;66:1732-40.